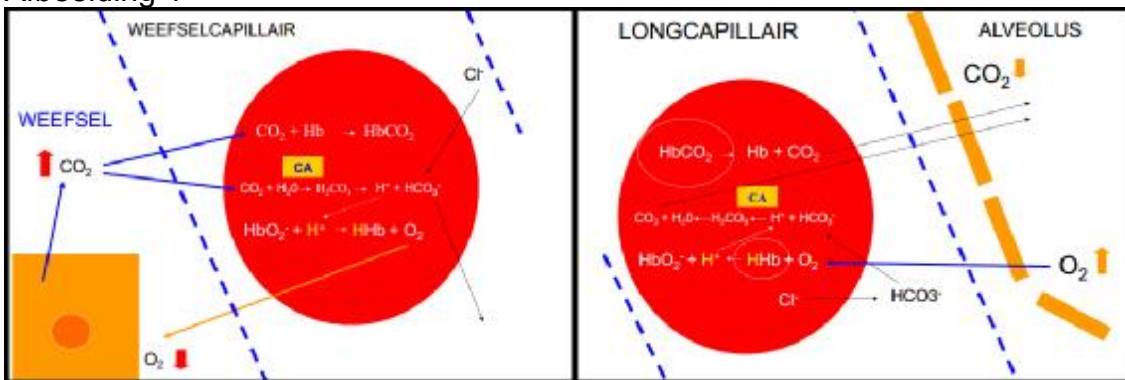
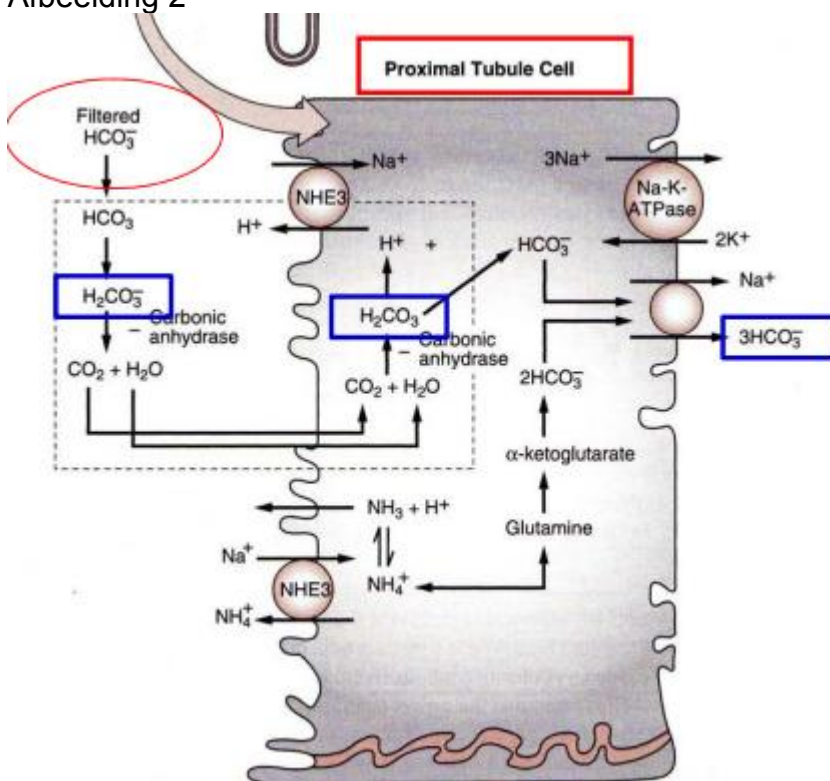


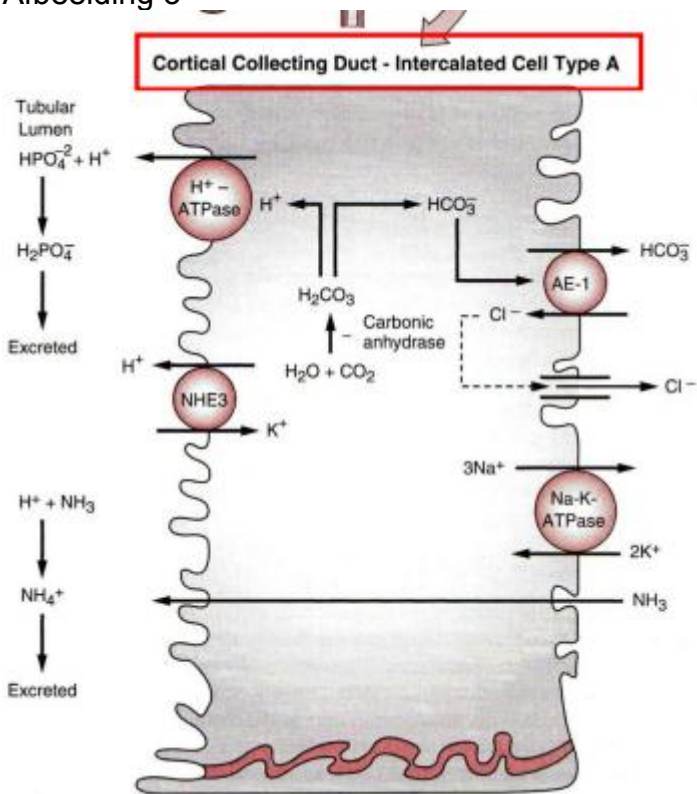
Afbeelding 1



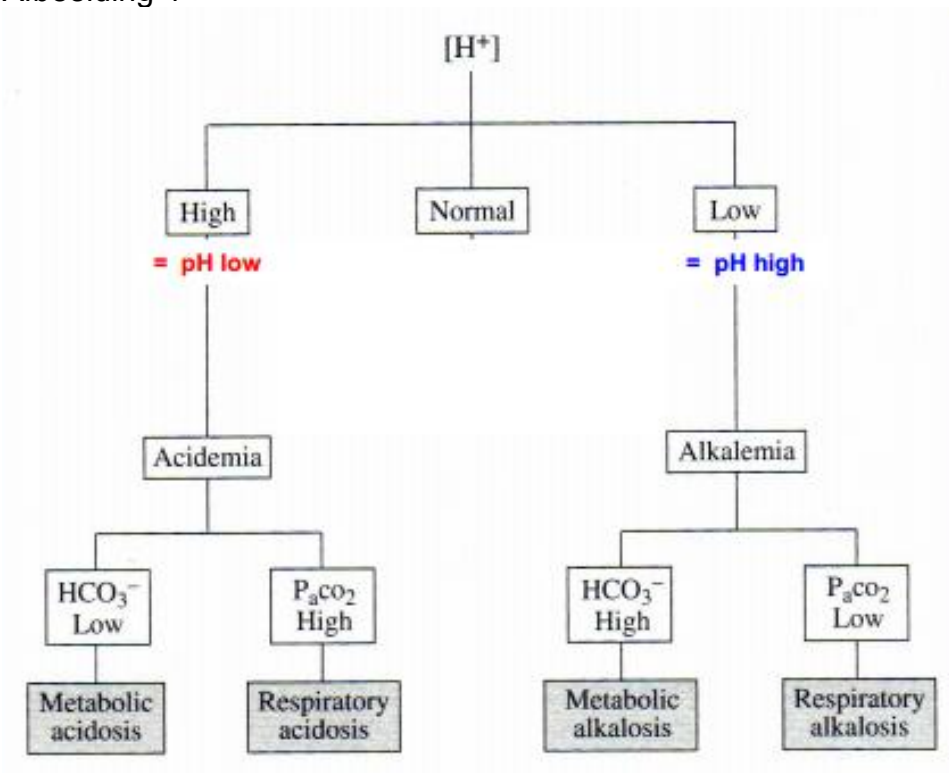
Afbeelding 2



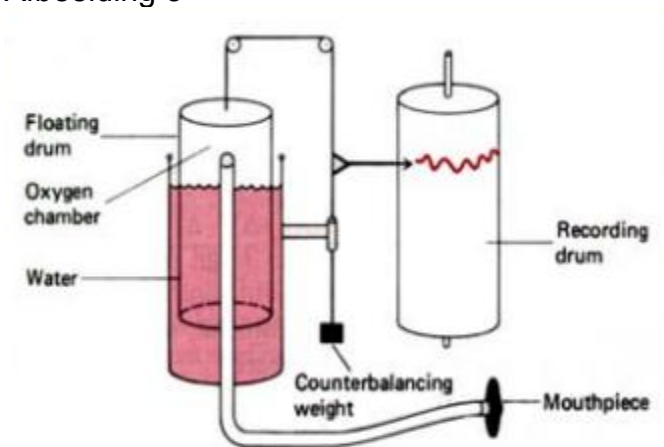
Afbeelding 3



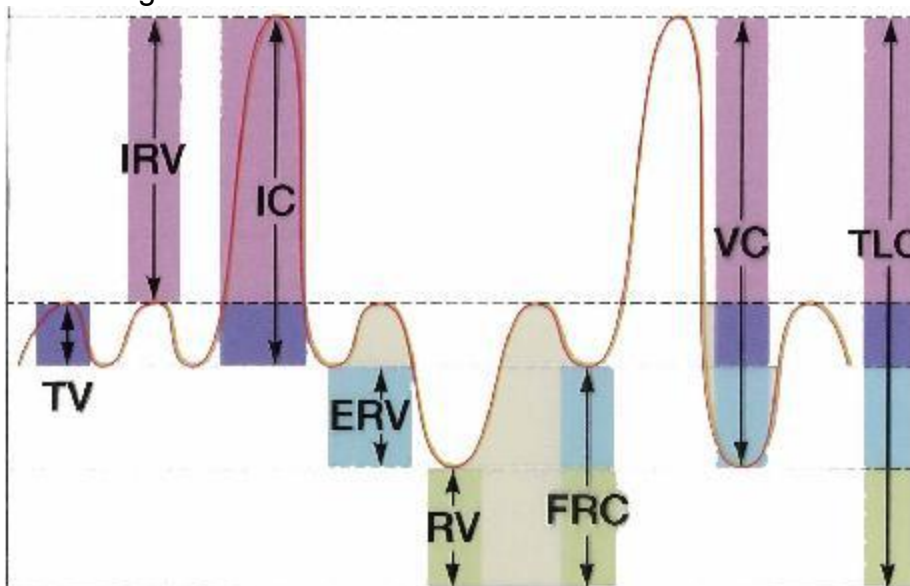
Afbeelding 4



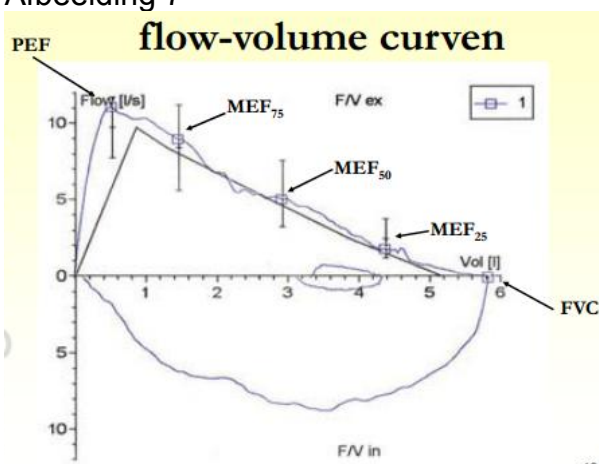
Afbeelding 5



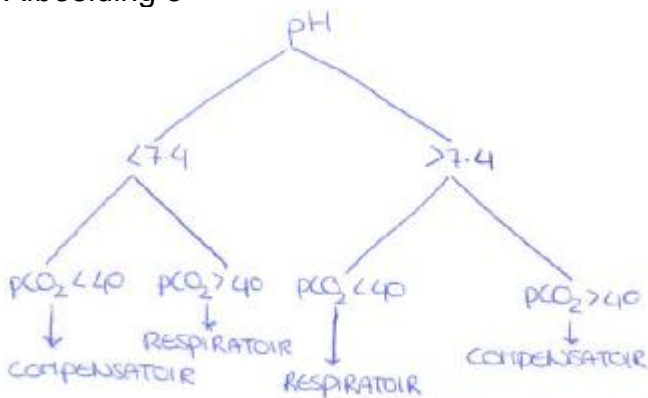
Afbeelding 6



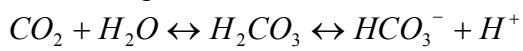
Afbeelding 7



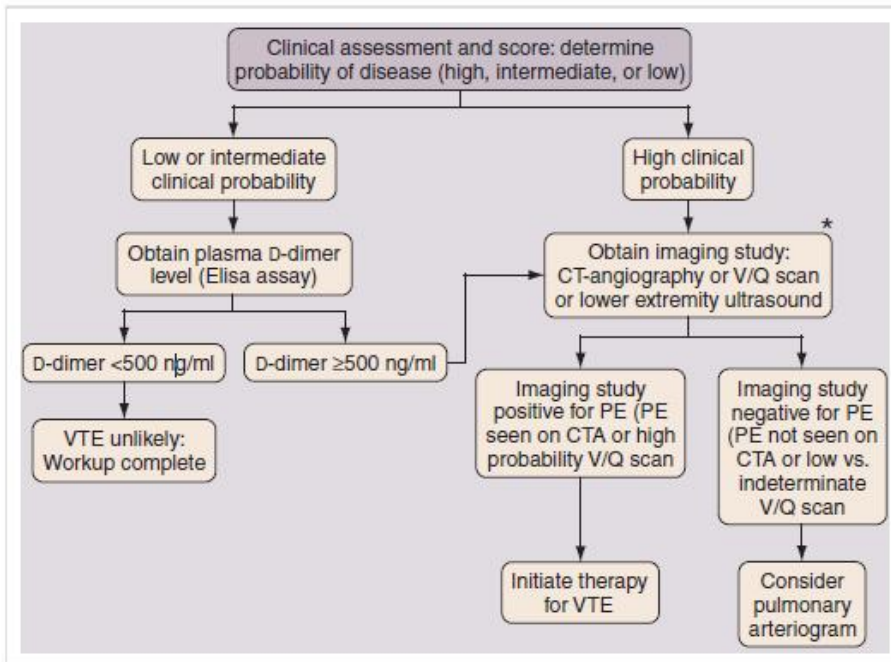
Afbeelding 8



Afbeelding 9



Afbeelding 10



## Afbeelding 11

Reported Value	Description	Interpretation
VC	Vital capacity Volume of air displaced by maximal exhalation or maximal inhalation maneuver	Typically preserved in obstruction, but reduced in restriction.
FVC	Forced vital capacity Volume forcefully exhaled from maximal inhalation (TLC) to maximal exhalation (RV), the FEVC maneuver	Pattern similar to VC, although more likely to be reduced in obstruction than VC. Used to grade severity of restriction.
FEV <sub>1</sub>	Forced expiratory volume in one second Volume exhaled in 1 <sup>st</sup> second of FEVC maneuver	Reduction typical of medium to large airways obstruction. Used to grade severity of obstruction.
FEV <sub>1</sub> /FVC	Ratio of FEV <sub>1</sub> to FVC	Reductions indicative of airway obstruction.
FEF <sub>25-75</sub>	Forced expiratory flow (25-75%) Mean expiratory flow rate in the middle half of FEVC maneuver	Sensitive but nonspecific indicator of small airways obstruction. Poorly reproducible, varies with effort and time of expiration.
FIVC	Forced inspiratory vital capacity Maximum volume forcefully inhaled from maximal exhalation, the FIVC maneuver	Inspiratory flows reduced in extrathoracic airways obstruction, correlate with MVV.
MVV	Maximum voluntary ventilation Estimate of one minute's maximal air displacement extrapolated from repeated inspiratory and expiratory efforts	Disproportionate reductions relative to FEV <sub>1</sub> may indicate upper airways obstruction, muscle weakness, or poor performance.
PEF	Peak expiratory flow Maximal sustained airflow achieved during the FEVC maneuver	Worsening may correlate with asthma exacerbations. Sometimes helpful in assessing subject effort.